



## The neuroanatomy of asomatognosia and somatoparaphrenia

Todd E Feinberg, Annalena Venneri, Anna Maria Simone, et al.

*J Neurol Neurosurg Psychiatry* 2010 81: 276-281 originally published online September 24, 2009  
doi: 10.1136/jnp.2009.188946

---

Updated information and services can be found at:  
<http://jnp.bmj.com/content/81/3/276.full.html>

---

*These include:*

### References

This article cites 28 articles, 12 of which can be accessed free at:  
<http://jnp.bmj.com/content/81/3/276.full.html#ref-list-1>

### Email alerting service

Receive free email alerts when new articles cite this article. Sign up in the box at the top right corner of the online article.

---

### Notes

---

To order reprints of this article go to:  
<http://jnp.bmj.com/cgi/reprintform>

To subscribe to *Journal of Neurology, Neurosurgery & Psychiatry* go to:  
<http://jnp.bmj.com/subscriptions>

# The neuroanatomy of asomatognosia and somatoparaphrenia

Todd E Feinberg,<sup>1,2</sup> Annalena Venneri,<sup>3,4</sup> Anna Maria Simone,<sup>4</sup> Yan Fan,<sup>5</sup> Georg Northoff<sup>6</sup>

<sup>1</sup>Albert Einstein College of Medicine, Bronx, New York, USA

<sup>2</sup>Yarmon Neurobehavior and Alzheimer's Disease Center, Beth Israel Medical Center, New York, USA

<sup>3</sup>Clinical Neuroscience Centre, University of Hull, Hull, UK

<sup>4</sup>Department of Neuroscience, University of Modena and Reggio Emilia, Modena, Italy

<sup>5</sup>Department of Psychiatry, Otto-von-Guericke University, Magdeburg, Germany

<sup>6</sup>University of Ottawa Institute of Mental Health Research, Ottawa, Canada

## Correspondence to

Dr Todd E Feinberg, Yarmon Neurobehavior and Alzheimer's Disease Center, Beth Israel Medical Center, First Avenue at 16th Street, New York, NY 10003, USA; [tfeinber@chpnet.org](mailto:tfeinber@chpnet.org)

Received 15 July 2009

Revised 4 September 2009

Accepted 13 September 2009

## ABSTRACT

**Objectives** Asomatognosia is broadly defined as unawareness of ownership of one's arm, while somatoparaphrenia is a subtype in which patients also display delusional misidentification and confabulation. Studies differ with regard to the underlying neuroanatomy of these syndromes.

**Methods** Three groups of patients with right-hemisphere strokes and left hemiplegia were analysed: G1, asomatognosia+neglect; G2, non-asomatognosia+neglect; G3, hemiplegia only. The asomatognosic group was further subdivided into somatoparaphrenia (G1-SP: asomatognosia+delusions/confabulation) and simple asomatognosia (G1-SA: asomatognosia without delusions/confabulation).

**Results** Patients with all forms of asomatognosia (G1) had larger lesions than non-asomatognosic patients in all sectors. While patients with or without asomatognosia had significant temporoparietal involvement, we found that the subset of patients with somatoparaphrenia had the largest lesions overall, and somatoparaphrenia cases had significantly more frontal involvement than patients with simple asomatognosia. All patients with asomatognosia (G1-SP and G1-SA) had significant medial frontal damage, suggesting that this region may play a role in the development of asomatognosia in general. Somatoparaphrenia cases also had greater orbitofrontal damage than simple asomatognosia cases, suggesting that the orbitofrontal lesion was critical in the development of somatoparaphrenia.

**Conclusions** Asomatognosia results from large lesions involving multiple—including temporoparietal—sectors, but the addition of medial frontal involvement appears important. The addition of orbitofrontal dysfunction distinguishes somatoparaphrenia from simple asomatognosia. The data indicate roles for the right medial and orbitofrontal regions in confabulation and self-related systems.

Asomatognosia, literally 'lack of recognition of the body,' is among the most striking self-related neurobehavioural syndromes. The most common form of asomatognosia is the non-recognition and denial of ownership of the left arm in the setting of right (non-dominant) hemisphere damage, left hemiplegia, left hemisensory deficits and hemispatial neglect.<sup>1–10</sup>

The form and degree of the asomatognosic response vary considerably among patients. Gerstmann<sup>5</sup>–<sup>6</sup> distinguished simple disturbances of memory or consciousness of the affected body parts—conditions he called autosomatamnesia and autosomatagnosia—from more elaborate delusional

and confabulatory manifestations that he termed 'somatoparaphrenia.' The term 'asomatognosia' was later introduced by Critchley<sup>1</sup> as broadly representing 'loss of awareness of one body-half.' These distinctions serve to emphasise the range of asomatognosic responses. Hence, in some cases of asomatognosia, patients appear simply unaware of, or confused regarding, the ownership of the limb. These patients may mistake their arm with the examiner's arm or simply profess ignorance to whom the arm belongs. In these patients, however, it is often the case that the error can be corrected if the true identity of the arm is pointed out to the patient or the patient traces the left arm up to its connection with the shoulder.

However, both Gerstmann<sup>5</sup> and Critchley<sup>1</sup>–<sup>2</sup> pointed out that in other cases of asomatognosia, the misidentification of the arm may have considerable confabulatory elaboration and be accompanied by elaborate delusions. In these circumstances, the patient adamantly insists that the arm is not her own, despite irrefutable proof that the arm is attached to the body, and the patient produces elaborate confabulations as to how the arm got there or who it 'really' belongs to. In some instances, the arm may even be treated like a child, given a nickname, or treated like a separate person with a separate identity.<sup>1</sup>–<sup>2</sup>–<sup>4</sup>–<sup>11</sup>

Investigations of the underlying anatomy of somatoparaphrenia have had varying results. One prior neuroanatomical study of asomatognosic patients found that the neuropathology in these cases was centred on the right supramarginal gyrus and thalamoparietal projections.<sup>3</sup> Baier and Karnath<sup>9</sup> found that a 'disturbed sensation of limb ownership' (DSO) was associated with right posterior insula damage. In a recent comprehensive literature review, Vallar and Ronchi<sup>6</sup> found that most prior studies of somatoparaphrenia indicated a primary role for posterior (temporo-parietal junction) lesions in the genesis of the condition, although there have been reports of cases with extensive fronto-temporo-parietal lesions.

None of these studies attempted to determine whether there were any anatomical differences between those cases that had uncomplicated errors of recognition, such as simply denying ownership or calling the arm the 'doctor's arm,' from those cases with adamant, refractory denial of ownership, and extended and repeated delusions and confabulations about the arm. It may be that further fractionation of clinical subtypes might reveal some finer-tuned clinical–anatomical relationships that could help explain some of the anatomical variability of prior studies of the syndrome.

**METHODS****Sample**

Cases in group G1 (n=13) were examined by one of the authors (TEF) and were selected retrospectively for the purposes of the current investigation. Cases in G2 (n=7) and G3 (n=6) were studied by AV. All cases underwent clinical neurological examinations, including evaluation for hemispatial neglect via line cancellation task<sup>12</sup> and brain imaging within 1 week of acute hospitalisation. The presence of asomatognosia was determined according to the standardised protocol described in Feinberg *et al.*<sup>3</sup> In this method, the examiner approaches the patient from the right-hand side and first raises the patient's right arm, asking the patient 'What is this?' If the patient correctly identifies the right arm, the examiner then brings the left arm into the right hemispace, and the question is repeated. Based upon their responses, patients were judged to be asomatognosic or non-asomatognosic. Additionally, if the patient produced extended beliefs, delusions or confabulations about the arm, these were recorded. All patients in groups 1–3 had acute right-hemisphere strokes and left hemiplegia. The demographics of the three groups are shown in table 1.

Thirteen cases met criteria for group 1: asomatognosia + neglect. All patients in this group had left hemiplegia, hemispatial neglect, severe proprioceptive and somatosensory defects, and at a minimum denied ownership of the left arm. However, consistent with the observations of Critchley<sup>1 2</sup> and Gerstmann,<sup>5</sup> there was a considerable range of responses regarding the asomatognosia that varied from simple denial of ownership to

extended delusional narratives about the identity of the arm. In the latter case, the confabulations and delusions were repeated on more than one occasion, were reported with great conviction and were relatively refractory to correction by the examiner. In order to explore potential anatomical differences that might correspond to the observed clinical variations in the extent and nature of the asomatognosia, the asomatognosic responses of each patient were also grouped according to the degree of confabulatory and delusional elaboration. The criteria for the presence of somatoparaphrenia (G1-SP) included the extent, degree and nature of the confabulations regarding the arm. Considerations used were the bizarreness of the misidentification, such as identifying the arm as an inanimate object, the length and degree of elaboration beyond simple misidentification or personal rejection of the arm, or the attribution of the arm to a person other than the examiner, such as a relative. We also noted the presence of other confabulatory elements regarding person or places, such as misidentifications or reduplications of persons or places. In this manner, asomatognosic cases were roughly grouped into a somatoparaphrenia subtype (G1-SP) who displayed the most extensive and refractory confabulatory or delusional content (cases G1-1 to G1-7) and a simple asomatognosia subtype (G1-SA) that displayed the least confabulatory content (cases G1-8 to G1-13; table 1; appendix).

In order to control for the influence of hemiplegia and neglect alone, seven cases in group 2: non-asomatognosia + neglect were identified that did not demonstrate either somatoparaphrenia or asomatognosia but did display hemiplegia and hemispatial neglect. Patients in group 2 were also found to have moderate proprioceptive and somatosensory defects. In order to control for the presence of hemiplegia only, six patients in group 3: hemiplegia only had hemiplegia without asomatognosia or neglect. These cases were found to have mild or absent proprioceptive and somatosensory defects. One group of subjects was examined by one author (AV) as part of a larger study approved by the local IRB, and informed consent was obtained. We also report subjects that were personally examined by one of the authors (TEF) over a 20-year period as part of their routine clinical care, and all cases examined over that period with sufficient data regarding the presence of asomatognosia and somatoparaphrenia were included in the investigation. The data regarding these examinations were analysed retrospectively; these cases were not part of a research protocol, and all data are deidentified and therefore considered exempt from IRB approval or informed consent.

**Table 1** Demographics of groups G1–G3

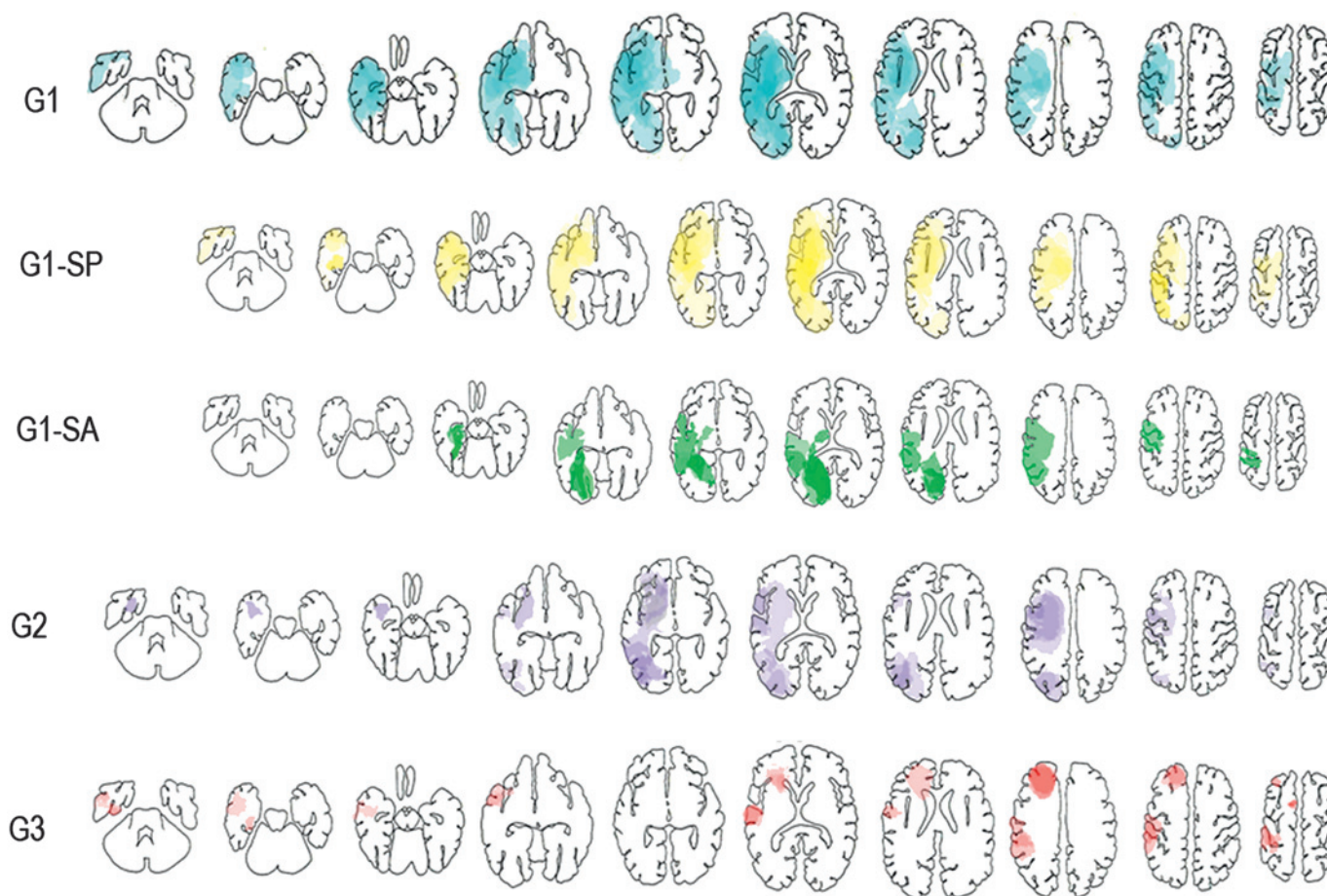
Group 1: asomatognosia		
Patient	Age/sex	Aetiology
G1-1	52/M	Ischaemic stroke
G1-2	75/M	Ischaemic stroke
G1-3	62/M	Ischaemic stroke
G1-4	81/F	Ischaemic stroke
G1-5	45/F	Haemorrhagic stroke
G1-6	53/M	Haemorrhagic stroke
G1-7	79/W	Ischaemic stroke
G1-8	73/M	Ischaemic stroke
G1-9	82/F	Ischaemic stroke
G1-10	82/F	Ischaemic stroke
G1-11	82/F	Ischaemic stroke
G1-12	64/M	Ischaemic stroke
G1-13	83/F	Ischaemic stroke
Group 2: non-asomatognosia + neglect		
G2-1	48/M	Ischaemic stroke
G2-2	57/F	Ischaemic stroke
G2-3	76/M	Ischaemic stroke
G2-4	81/M	Ischaemic stroke
G2-5	67/M	Ischaemic stroke
G2-6	64/F	Ischaemic stroke
G2-7	85/M	Ischaemic stroke
Group 3: hemiplegia only		
G3-1	68/M	Ischaemic stroke
G3-2	66/F	Ischaemic stroke
G3-3	44/F	Ischaemic stroke
G3-4	37/M	Ischaemic stroke
G3-5	40/F	Ischaemic stroke
G3-6	50/M	Ischaemic stroke

All patients have left hemiplegia. Patients in group 1 had severe, group 2 moderate, and group 3 mild or no proprioceptive and somatosensory defects.

G1, all asomatognosic cases; G2, non-asomatognosia with hemispatial neglect; G3, only hemiplegia.

**Lesion identification and quantification**

All patients had been scanned with CT within a week of hospitalisation. Lesions for each patient were drawn manually on each scan in their own native space (CT scan) and superimposed onto the specific Damasio and Damasio's<sup>13</sup> template that best matched the orientation of the tomographic image. A digital fitting of each lesion onto the template was carried out for each patient, to convert lesions from native space into standard template space. Lesion size in mm<sup>3</sup> was determined from the converted standard template space (by multiplying the two-dimensional lesion size by slice thickness). The brain areas involved with the lesion in each patient were identified using the Brodmann areas (BAs) labelling marked on each patient's summary template. A summary template for each group was then obtained by overlaying each patient lesion summary onto one template per group. A summary template for each group was then obtained by overlaying each patient lesion summary onto one template per group (Figure 1)



**Figure 1** Templates of groups. G1, all asomatognosia cases; G1-SP, asomatognosia with delusions/confabulation; G1-SA, asomatognosia without delusions/confabulation; G2, non-asomatognosia with hemiplegia and hemispatial neglect; G3, hemiplegia only. G1, 13 cases; G1-SP, 7 cases; G1-SA, six cases; G2, seven cases and G3, six cases. Lesions for each patient were drawn manually on each scan in their own native space (CT scan) and superimposed onto the specific Damasio and Damasio's<sup>13</sup> template that best matched the orientation of the tomographic image.

## RESULTS

The total number of cases with involvement in each anatomical sector is shown in table 2. Patients with all forms of asomatognosia (G1) had larger lesions than non-asomatognosic patients in all sectors. A  $\chi^2$  test comparing G1 (13 patients) and G2+G3 (13 patients together) found that G1 had larger lesions in the frontal lobe ( $\chi^2(1)=5.556$ ,  $p<0.05$ ), the temporal lobe ( $\chi^2(1)=14.519$ ,  $p<0.001$ ), the parietal lobe ( $\chi^2(1)=4.083$ ,  $p<0.05$ ) and the occipital lobe ( $\chi^2(1)=8.805$ ,  $p<0.01$ ). G1 also had more lesion involvement than G2+G3 in the medial frontal lobe ( $\chi^2(1)=5.000$ ,  $p<0.05$ ) but not the lateral frontal lobe ( $\chi^2(1)=0.818$ ,  $p>0.1$ ) or the orbital frontal lobe ( $\chi^2(1)=2.000$ ,  $p>0.1$ ).

When asomatognosic subgroups were considered, we found that G1-SP showed more lesion involvement than G1-SA in the frontal, temporal, parietal and occipital lobe ( $p<0.001$ ). G1-SP also showed more lesion involvement than G2 in the frontal ( $p<0.002$ ) and temporal ( $p<0.001$ ) lobes but not in the parietal occipital lobes. G1-SP showed more involvement than G3 in all lobes ( $p<0.001$ ). In terms of the total burden of involvement, there were no significant differences between G1-SA and G2, and there were no significant differences in lesion involvement between G1-SA and G3 in the frontal or the temporal lobe, but G1-SA had more lesion involvement than G3 in the parietal lobe ( $\chi^2(1)=5.333$ ,  $p<0.05$ ) and the occipital lobe (G1-SA=19, G3=0).

Within frontal subsectors, we found that G1-SP showed more involvement than G1-SA in the medial frontal lobe ( $\chi^2(1)=$

14.000,  $p<0.001$ ), the lateral frontal lobe ( $\chi^2(1)=24.000$ ,  $p<0.001$ ) and the orbital frontal lobe (G1-SP=6, G1-SA=0). However, when the degree of frontal damage was measured as a function of the percentage of cases with involvement within frontal subsectors (table 3), we again found that G1-SP cases had the greatest cumulative burden of damage compared with all other groups, but both G1-SP and G1-SA had more cases with any medial damage compared with that seen in G2 and G3. Finally, although G1-SP and G1-SA did not differ from each other in the percentage of patients with medial damage, there was much greater frontal orbital damage in G1-SP when compared with G1-SA (G1-SP 57.14% vs G1-SA 0%). Finally, although a greater percentage of G1-SP cases had lateral frontal involvement when compared with G1-SA (G1-SP 100% vs G1-SA 16.67%), G2 also showed 100% lateral involvement, and G3 had 83.33% lateral involvement, suggesting that lateral frontal involvement, at least alone or even in combination with parietal damage, did not distinguish the asomatognosic from the non-asomatognosic patients.

## DISCUSSION

In this investigation, we confirmed previous reports implicating parietal and temporo-parietal damage in asomatognosia,<sup>1-6</sup> and further that there are significant anatomical differences between asomatognosic, confabulatory/delusional asomatognosic and non-asomatognosia patients. We first found that patients with

**Table 2** Lesion locations of groups G1–G3

Lobe	Region	Structure	BA	G1	G1-SP	G1-SA	G2	G3	
Frontal lobe	Mesial aspect	Cingulate gyrus anterior	24	7	5	2	1	1	
		Cingulate gyrus posterior	23, 31	5	2	3	1	0	
		Supplementary motor area	6	1	1	0	0	1	
		Prefrontal region	8, 9, 10	1	1	0	1	0	
		Rolandic region	4, 3, 1, 2	1	1	0	0	0	
	Lateral aspect	Frontal operculum	44, 45	4	4	0	1	2	
		Prefrontal region	8, 9, 46	3	3	0	1	1	
		Premotor region-rolandic r	6, 4, 3, 1, 2	7	6	1	7	3	
		Paraventricular		5	5	0	0	1	
		Supraventricular area		6	5	1	1	2	
	Orbital aspect	Anterior	10	1	1	0	0	0	
		Posterior	11, 12, 13, 47	2	2	0	0	0	
		Basal forebrain		0	0	0	0	0	
Subventricular area			3	3	0	2	0		
Middle temporal gyrus anterior		21	4	3	1	1	1		
Temporal lobe	Lateral/superior aspect	Middle temporal gyrus posterior	37	4	3	1	3	0	
		Inferior temporal gyrus anterior	20	1	1	0	0	1	
		Inferior temporal gyrus posterior	37	3	2	1	0	0	
		Auditory region	41, 42	1	1	0	0	0	
		Anterior to auditory region	22	5	4	1	1	1	
		Posterior to auditory region	22	10	7	3	2	0	
	Mesial aspect	Anterior (amygdala)	28, 36	5	4	1	1	0	
		Posterior (hippocampus)	28, 36	5	1	4	0	1	
		Polar area	38	3	3	0	0	1	
	Parietal lobe	Inferior parietal lobule	Supramarginal gyrus	40	8	7	1	5	1
			Angular gyrus	39	5	3	2	5	0
		Superior parietal lobule	Lateral	7, 5	4	3	1	2	1
			Mesial	7, 5	4	1	3	1	0
Paraventricular area				6	4	2	1	0	
Occipital lobe	Mesial aspect	Supraventricular area		4	3	1	1	0	
		Infracalcarine	18, 19	3	1	2	0	0	
		Supracalcarine	18, 19	4	1	3	0	0	
	Lateral aspect	Temporo-occipital junction	37, 36	3	0	3	0	0	
		Inferior	18, 19	4	2	2	3	0	
		Superior	18, 19	5	2	3	4	0	
		Paraventricular area		8	4	4	3	0	
Insula		Forceps major		3	1	2	1	0	
		Anterior		0	0	0	0	0	
		Posterior		1*	1*	0	0	0	

\*Partial involvement.

The numbers represent the total number of cases with involvement in each anatomical sector. G1, asomatognosia; G1-SA, asomatognosia without delusions/confabulation; G1-SP, asomatognosia with delusions/confabulation; G2, non-asomatognosia with hemiplegia and hemispatial neglect; G3, hemiplegia only. BA, Brodmann areas; G1, 13 cases; G1-SA, six cases; G1-SP, seven cases; G2, seven cases; G3, six cases.

all forms of asomatognosia (G1) had larger lesions than non-asomatognosic patients in all sectors. However, although parietal involvement has been frequently implicated in the genesis of asomatognosia, when we consider the three subgroups with hemispatial neglect (G1-SP, G1-SA and G2) there were no differences either in the overall degree of (table 2) or the percentage of cases (table 3) with parietal involvement, suggesting that parietal involvement is a necessary but not sufficient condition for the occurrence of asomatognosia. On the other hand, temporal involvement was also greater in the confabulatory asomatognosic patients, which suggests a contribution from damage in this region, as has been previously reported.<sup>6</sup>

Interestingly, we also found that as a group, G1 patients had greater frontal involvement than the non-asomatognosia patients. G1 had a greater burden of frontal involvement in all subsectors examined (medial, lateral and orbital) when compared with G2, and a greater percentage of G1 cases overall had extensive frontal damage when compared with G2 (table 3).

However, the extent of this difference varied among anatomical subsectors and clinical subgroups. Both simple asomatognosia (G1-SA) and somatoparaphrenia (G1-SP) cases had a greater percentage of cases with medial frontal damage than G2 and G3, suggesting that this region may play a role in the development of asomatognosia in general. While somatoparaphrenia cases had greater lateral and orbitofrontal damage than simple asomatognosia cases, both non-asomatognosic groups (G2 and G3) also had extensive lateral damage, suggesting that the orbitofrontal lesion was critical in the development of somatoparaphrenia versus simple asomatognosia. Thus, when the data are considered as a whole, it appears that asomatognosia in general occurs most commonly in the setting of temporoparietal damage, hemispatial neglect and medial frontal damage. The combination of right temporoparietal, mediofrontal and orbitofrontal dysfunction may distinguish somatoparaphrenia from simple asomatognosia and non-asomatognosic patients.

It is not immediately clear why the medial prefrontal damage would be implicated in the production of asomatognosia and

## Research paper

**Table 3** Percentage of cases with at least one lesion in the divided sectors noted in table 2

		G1 (%)	G1-SP (%)	G1-SA (%)	G2 (%)	G3 (%)
Frontal	Mesial	84.61	85.71	83.33	14.29	33.33
	Lateral	61.54	100	16.67	100	83.33
	Orbital	30.77	57.14	0	28.57	0
Temporal	Lateral/superior	76.92	100	50	57.14	16
	Mesial	69.23	71.43	66.66	14.29	33
Parietal	Inferior parietal	69.23	100	33.33	85.71	16
	Superior parietal	76.92	85.71	66.66	28.57	16
Occipital	Mesial	69.23	57.14	66.66	0	0
	Lateral	69.23	57.14	83.33	57.14	0
Insula		8*	14*	0	0	0

\*Partial involvement.

G1, all asomatognosia cases; G1-SA, asomatognosia without delusions/confabulation; G1-SP, asomatognosia with delusions/confabulation; G2, non-asomatognosia with hemiplegia and hemispatial neglect; G3, hemiplegia only. G1, 13 cases; G1-SA, six cases; G1-SP, seven cases; G2, seven cases; G3, six cases.

somatoparaphrenia, since prior research has not reported prominent medial prefrontal cortex damage in these syndromes<sup>3 6</sup> However, these regions have been implicated more generally in a host of other self-related functions.<sup>14 15</sup> The medial prefrontal cortex is one of the heteromodal association cortical regions that are situated between the paralimbic zones that are most allied with the limbic functions of the maintenance of homeostasis and the conditions of the internal milieu, and the unimodal zones that represent the most abstract aspects of sensorimotor processing.<sup>16</sup> These regions serve as a 'convergence zone'<sup>17</sup> for the integration of the other two systems. It has been proposed that an integrative self system serves to assimilate and mediate the organism's internal needs and self-representation with the external environment.<sup>4</sup> Since this region is intimately concerned with distinguishing the self from the world, damage to this system could cause confusion between the internal representation of the self (one's own arm) and external stimuli (another's arm) and contribute to the asomatognosic response.

While all asomatognosic patients had temporoparietal and medial frontal damage, patients with somatoparaphrenia had a significantly greater involvement of orbitomedial frontal cortex, another heteromodal region that also serves as a critical integration zone between internal (interoceptive) and external (exteroceptive) information. Further and significantly for our understanding of the role that orbitomedial prefrontal cortical damage might play in the production of somatoparaphrenia is the association between frontal and orbitofrontal damage and confabulation.<sup>18–24</sup>

There have been prior attempts to explain the presence of confabulations regarding the paralysed left arm in patients with right-hemisphere lesions. Geschwind<sup>25</sup> proposed that some confabulatory responses were based upon a disconnection of perceptual regions from the language areas of the verbal (left) hemisphere. When the verbal hemisphere lacks the requisite knowledge regarding the left-side hemispace, and the left side of the body, the patient fills in the information by the process of perceptual completion. Like Geschwind, Gazzaniga<sup>26 27</sup> argues that the left hemisphere serves an 'interpreter' function, and when faced with incomplete information, it tends to construct elaborate and false interpretation of events in an effort to 'make sense' of actions or perceptions whose content or cause is actually unknown.

According to the Geschwind–Gazzaniga account, it is plausible that confabulation could arise from incomplete information within the left hemisphere, an idea that is consistent with

theories that invoke the 'gap filling' functions of neutral confabulations as demonstrated by some amnesic patients.<sup>28 29</sup> However, this account is less able to explain the delusional, fixed, self-referential and bizarre aspects of the confabulations displayed by our somatoparaphrenic patients who went far beyond simple misidentification or 'gap filling.'

In a recent comprehensive review of confabulation, Schnider<sup>19</sup> describes four subtypes of confabulation: intrusions or simple provoked confabulations that occur during memory tests, momentary confabulations that occur in the context of conversations or questions, fantastic confabulations that have no basis in reality and tend towards the nonsensical, and behaviourally spontaneous confabulations, which reflect an abnormal 'adaptation of thought to ongoing reality' and are the result of a failure to suppress currently irrelevant memories to ongoing experience (temporal context confusions). Schnider also distinguishes mnesic confabulation in patients whose confabulation is based primarily upon memory failure from non-mnesic confabulations that derive from false perceptions of the body and the world. According to these criteria, the confabulations in the somatoparaphrenia cases were 'fantastic' in type and closer clinically to other forms of delusional misidentification<sup>30–34</sup> than they are to the other varieties of confabulation as outlined by Schnider<sup>19</sup>. It is possible that fantastic confabulation as demonstrated by the somatoparaphrenic patients may be more tightly associated with orbitofrontal lesions. Additionally, in contrast to mnesic confabulators whose lesions are not lateralised,<sup>35</sup> there is a higher incidence of right frontal lesions among patients with delusional confabulation, misidentification and somatoparaphrenia.<sup>36–38</sup>

## CONCLUSIONS

In summary, it appears that there are at least three interacting neuroanatomically based factors that contribute to the somatoparaphrenic response. First, all cases in our investigation had temporoparietal lesions and hemispatial neglect. This factor makes an important, possibly necessary but insufficient, contribution to the syndromes of both simple asomatognosia and somatoparaphrenia. Second, all asomatognosic patients had medial frontal lesions that appear critical for the disownership of the limb. Finally, an additional right orbitofrontal lesion appears to contribute to the extended and confabulatory responses typical in the full syndrome of somatoparaphrenia. It must be noted, however, that not all cases with a large right-hemisphere lesion display somatoparaphrenia or confabulation. This further suggests that there may be other factors that come into play, perhaps via the intact left hemisphere—such as premorbid personality, defensive or motivational factors—that make a contribution to the overall syndrome.<sup>4</sup>

There are several limitations to this investigation. We did not have full neuropsychological data on our cases. It would be of interest to know whether G1 cases also had executive impairments that corresponded to their frontal lesions. Further, although our cases were examined for the presence of extrapersonal neglect, we did not obtain independent measures of personal neglect, and had we done so, it is possible that other differences between G3 and groups G1 and G2 on this measure might have emerged. We did not perform formal evaluations for anosognosia, and the relationship between asomatognosia and this condition would also be of interest. Future investigations could explore the influence and role of these other variables in the production of asomatognosia. Finally, although we attempted to retrospectively quantify and characterise the degree and type of asomatognosia and somatoparaphrenia,

future studies would benefit from the development of scales that could help with this distinction. In spite of these shortcomings, we believe that our findings indicate a potential role for frontal impairments in asomatognosia and somatoparaphrenia that warrants further consideration.

**Acknowledgements** The authors wish to thank G Vallar and A Schnider for helpful discussions and suggestions on an earlier draft of this paper.

**Funding** This study was supported in part by The Gerald J and Dorothy R Friedman New York Foundation for Medical Research (to TEF); MIUR, the Italian Ministry for Education, University and Research (to AV); The Hope of Depression Research Foundation (HDRF) and German Research Foundation with the SFB 779 (A6) (to GN).

**Competing interests** TEF has been on the speaker's bureau or participated in CME programmes sponsored by Esai/Pfizer, Novartis and Forest Pharmaceuticals. AV has received educational grant support, travel support and speaker's fees from Novartis Pharmaceuticals. AMS has received educational fellowships from Bayer and Serono Pharmaceuticals.

**Ethics approval** Ethics approval was provided by the Comitato Etico Provinciale di Modena.

**Patient consent** Obtained.

**Provenance and peer review** Not commissioned; externally peer reviewed.

## REFERENCES

- Critchley M. *The parietal lobes*. New York: Hafner Press, 1953.
- Critchley M. Personification of paralyzed limbs in hemiplegics. *BMJ* 1955;**30**:284–7.
- Feinberg TE, Haber LD, Leeds NE. Verbal asomatognosia. *Neurology* 1990;**40**:1391–94.
- Feinberg TE. *From axons to identity: neurological explorations of the nature of the self*. New York: W.W. Norton, 2009.
- Gerstmann J. Problem of imperception of disease and of impaired body territories with organic lesions. *Arch Neurol Psychiatry* 1942;**48**:890–913.
- Vallar G, Ronchi R. Somatoparaphrenia: a body delusion. A review of the neuropsychological literature. *Exp Brain Res* 2009;**192**:533–51.
- Meador KJ, Loring DW, Feinberg TE, et al. Anosognosia and asomatognosia during intracarotid amobarbital inactivation. *Neurology* 2000;**55**:816–20.
- Feinberg TE, Roane DM, Ali J. Illusory limb movements in anosognosia for hemiplegia. *J Neurol Neurosurg Psychiatry* 2000;**68**:511–13.
- Baier B, Karnath H-O. Tight link between our sense of limb ownership and self-awareness of actions. *Stroke* 2008;**39**:486–8.
- Halligan PW, Marshall JC, Wade DT. Unilateral somatoparaphrenia after right hemisphere stroke: a case description. *Cortex* 1995;**31**:173–82.
- Feinberg TE, DeLuca J, Giacino JT, et al. Right hemisphere pathology and the self: delusional misidentification and reduplication. In: Feinberg TE, Keenan JP, eds. *The lost self: pathologies of the brain and identity*. New York: Oxford University Press 2005:100–30.
- Albert ML. A simple test of visual neglect. *Neurology* 1973;**23**:658–64.
- Damasio H, Damasio AR. *Lesion analysis in neuropsychology*. New York: Oxford University Press, 1989.
- Northoff G, Bempohl F. Cortical midline structures and the self. *Trends Cogn Sci* 2004;**8**:102–7.
- Northoff G, Heinzel A, de Greck M, et al. Self-referential processing in our brain: a meta-analysis of imaging studies on the self. *Neuroimage* 2006;**31**:440–57.
- Mesulum M-M. *Principles of behavioral and cognitive neurology*. 2nd edn. New York: Oxford, 2000.
- Damasio AR. The brain binds entities and events by multiregional activation from convergence zones. *Neural Comput* 1989;**1**:123–32.
- Ptak R, Schnider A. Spontaneous confabulations after orbitofrontal damage: the role of temporal context confusions and self-monitoring. *Neurocase* 1999;**5**:243–50.
- Schnider A. *The confabulating mind: how the brain creates reality*. New York: Oxford, 2008.
- Schnider A, Ptak R. Spontaneous confabulators fail to suppress currently irrelevant memory traces. *Nat Neurosci* 1999;**2**:677–81.
- DeLuca J. Predicting neurobehavioral patterns following anterior communicating artery aneurysm. *Cortex* 1993;**29**:639–47.
- Fischer RS, Alexander MP, D'Esposito M, et al. Neuropsychological and neuroanatomical correlates of confabulation. *J Clin Exp Neuropsychol* 1995;**17**:20–8.
- DeLuca J, Diamond BJ. Aneurysm of the anterior communicating artery: A review of the neuroanatomical and neuropsychological sequelae. *Clin Exp Neuropsychol* 1995;**17**:100–21.
- Kapur N, Coughlan AK. Confabulation and frontal lobe dysfunction. *J Neurol Neurosurg Psychiatr* 1980;**43**:461–63.
- Geschwind N. Disconnexion syndromes in animals and man. *Brain* 1965;**88**:585–644.
- Gazzaniga MS. *The social brain*. New York: Basic Books, 1985.
- Gazzaniga MS. Cerebral specialization and interhemispheric communication: does the corpus callosum enable the human condition? *Brain* 2000;**123**:1293–326.
- Bonhoeffer K. *Die akuten geisteskrankheiten der gewohnheitstrinker*. Jena: Gustav Fischer, 1901.
- Bonhoeffer K. Der Korsakowsche Symptomenkomplex in seinen Beziehungen zu den verschiedenen Krankheitsformen. *Allg Z Psychiatrie* 1904;**61**:744–75.
- Vié J. Un trouble de l'identification des personnes: L'illusion des sosies. *Ann Med Psychol (Paris)* 1930;**88**:214–37.
- Vié J. Les meconnaissances systematiques. *Ann Med Psychol (Paris)* 1944;**102**:410–55.
- Feinberg TE. Confabulation, the self, and ego functions: The 'Ego Dysequilibrium Theory'. In: Hirstein W, ed. *Confabulation: views from neuroscience, psychiatry, psychology and philosophy*. New York: Oxford 2009:91–107.
- Feinberg TE, Roane DM. Delusional misidentification syndromes. In: Riggio S, ed. *Psychiatr Clin North Am* 2005;**28**:665–83.
- Devinsky O. Delusional misidentifications and duplications. *Neurology* 2009;**72**:80–7.
- Johnson MK, Hayes SM, D'Esposito M, et al. Confabulation. In: Grafman J, Boller F, eds. *Handbook of Neuropsychology*, 2nd edn. Amsterdam, Netherlands: Elsevier Science, 2002:383–407.
- Feinberg TE, Keenan JP. Where in the brain is the self? *Conscious Cogn* 2005;**14**:661–78.
- Malloy PF, Richardson ED. The frontal lobes and content-specific delusions. *J Neuropsychiatry Clin Neurosci* 1994;**6**:455–66.
- Bruen PD, McGeown WJ, Shanks MF, et al. Neuroanatomical correlates of neuropsychiatric symptoms in Alzheimer's disease. *Brain* 2008;**131**:2455–63.

## APPENDIX

The verbalisations of the cases of asomatognosia (G1=13 cases). Cases G1-1 through G1-7 were judged to display the greatest degree of confabulation (G1-SP). Cases G1-8 through G1-13 were judged to show the least confabulation (G1-SA).

**G1-1** 'I Told my brother to remind me to take this thing home with me or I'll leave it here... And I remember waking up and saying 'Good Lord!' I gotta get up and pack this before I leave or I'll leave it here... I was gonna pack it, not leave it here... Its a piece of useless equipment. (Also expressed the belief that there were 'three or four' hospitals with the same name (reduplicative confabulation).)

**G1-2** 'A remote control' 'A telephone pole' 'A dummy hand...Its a dummy'

**G1-3** 'Miss Mary's hand' 'Mother-in-law's hand' 'Miss Mary's my mother-in-laws hand' 'My mother's in the hospital right now...she had a stroke'

**G1-4** 'A stock...a stock' 'A stock option probably' 'A perfume bottle...looks like a perfume bottle' 'I have to get out of this firetrap' She confabulated that there were four hospitals with the identical name (reduplicative confabulation).

**G1-5** 'A hand that was left on the subway and they brought it here and they put it on me' (This narrative was repeated several times in essentially the same form.)

**G1-6** 'It's supposed to be my arm, but I think it's my brother's arm. I tell that to everyone but they don't believe me. My brother was on the wrong track for a while, and he got involved with some gangsters. They chopped off his arms and threw them in the river. I found this in my coffin. (Touching the left arm) Some people thought I was dead, and it was there. I don't know why I was in a coffin... after I was carried to the hospital... I was in a coffin...that's what I remember...I was laying next to this arm (pointing to left arm)...I was in a coffin....Yeah that's how I found it... I was alive...I didn't die...I found the arm in the coffin.

**G1-7** 'A breast' 'A deodorant' She produced extended confabulations about her husband's 'hands' who had died and left his hands behind. 'He left them... He didn't want them... He just left them like he left his clothes...Up until the other day. They used to fall on my chest. I said "I got to get rid of them!"...Put them in the garbage... Yes... 2 days ago... Still in the garbage...a black hand, with a plastic cover... you'll find them... Be careful, though...the nails are very long...and very sharp!'

**G1-8** 'I don't know' 'I don't know what it is' 'I'm not sure' 'I see it's a hand' 'I've seen it at many meals.'

**G1-9** 'Your (the doctor's) hand'

**G1-10** 'Your (the doctor's) hand'

**G1-11** 'A hand' 'Not mine' 'I don't know' 'A strange' 'I don't know' (who it belongs to) 'My hand and the strange hand'

**G1-12** 'One arm' 'A hand' 'Your (the doctor's) hand'

**G1-13** 'The doctor's hand' 'I'm not sure'